Journal Pre-proof

Perforated appendix in a neonate: a review of literature and case report from northern tanzania.

Lodhia Jay, Philemon Rune, Wapalila Daudi, Sadiq Adnan, Amsi Patrick, Msuya David, Herman Ayesiga

DOI: **********

Reference: AAS-2020-0007

To appear in: *Annals of African Surgery*

Received Date: 27-Jan-2020

Revised Date: 08-May-2020

Accepted Date: 09-Jun-2020

Please cite this article as: Lodhia J, Philemon R, Wapalila D, Sadiq A, Amsi P, Msuya D, Herman A. Perforated appendix in a neonate: a review of literature and case report from northern tanzania. *Annals of African Surgery*. 2020 [In Press].

Perforated appendix in a neonate: a review of literature and case report from northern tanzania.

Lodhia Jay, Philemon Rune, Wapalila Daudi, Sadiq Adnan, Amsi Patrick, Msuya David, Herman Ayesiga

Kilimanjaro Christian Medical Center, Moshi, United Republic of Tanzania.

Correspondence to:

Lodhia Jay

Department of General Surgery,

Kilimanjaro Christian Medical Center,

Moshi, United Republic of Tanzania.

Email: jlodhia2002@yahoo.com

Summary

Acute perforated appendicitis is rare in neonates and is associated with high morbidity and mortality. This is mainly because the rarity of the pathology and abnormal clinical features, cause delays in diagnosis and definitive management.

This is a case report of a premature neonate who presented with sudden onset of abdominal distension associated with inability to pass stools. Upon initial abdominal x-ray, free air under the right hemi diaphragm was seen. Emergency laparotomy was done where intra operatively there was a perforation at the appendicular tip. Appendectomy was done and the neonate recovered well with mild surgical site infection during the course to recovery.

Neonatal perforated appendicitis is rare and clinicians need to consider it as a differential diagnosis due to the atypical presentations. We report of an unusual case of a preterm neonate who presented with clinical features of intestinal obstruction and found at laparotomy perforated appendix at the tip due to neonatal appendicitis.

Keywords: Neonate, Neonatal appendicitis, Neonatal perforated appendicitis

Introduction

Acute appendicitis is the commonest surgical condition among children and the cause remains elusive (1). The appendix is like a tubular structure at the caecum with an average length of 4.5 cm in neonates and 9.5 cm in adults (2). The base of the appendix is wider in neonates and infants therefore the chances of luminal obstruction are rare (2). We present an unusual case of a premature neonate with perforated appendicitis where diagnosis was made intra operatively. This is an uncommon phenomenon with atypical presentations.

Case presentation

A premature male baby who was referred to us with presenting complaints of being born before term and difficulty in breathing since birth. This baby was the second twin, born vaginally and had an APGAR score of 8 and 10 in the first and fifth minutes respectively. The mother reported that the pregnancy was uneventful. At admission, diagnosis of a preterm baby at 32 weeks of gestation age by Finstorm was made as well as idiopathic respiratory distress syndrome. The patient was started on intravenous ampicillin and gentamycin to prevent infections, intramuscular vitamin K to prevent hemolysis and oxygen therapy.

On the fifth day it was reported that the baby was breastfeeding poorly, started to develop jaundice, had gradual abdominal distension and failure to pass stools. The patient was started on phototherapy for jaundice. An urgent plain erect abdominal x-ray was done which revealed free air under the right hemi diaphragm (Figure 1). The baby was then taken for an emergency laparotomy where intra-operatively, there was approximately 25 milliliters of ascitic fluid contaminated with fecal matter and a hyperemic appendix with a perforation at its tip (Figure 2). Other viscera were normal. Appendectomy was done and taken for histopathological analysis

(which later confirmed appendicitis [Figure 3]). Thorough lavage of the abdominal cavity was done and an abdominal drain was inserted. Post operatively the baby developed surgical site infection on the eighth day for which daily dressing was done and the patient recovered. On day 18 the patient was discharged from hospital. The baby was then seen at the neonatal outpatient clinic two weeks after discharge with good recovery and growth.

Discussion

Acute neonatal appendicitis is rare, and rate of perforation is higher in premature infants resulting in peritonitis (2,3). The incidence of neonatal appendicitis has been reported to be 0.04-0.2% by El-Gohary and this is infrequent because of the wide appendix at the base, soft liquid diet, recumbent posture and infrequent viral infections (3,4). The author also continues to state that of all reported cases, 25-50% is of premature infants and this is due to the underdeveloped immunity, thin appendiceal wall and indistensible caecum (3,5). Similar to our case, the diagnosis of perforation of the appendix is usually made operatively (3).

Primary neonatal appendicitis may present as an isolated entity where the etiology remains unclear but secondary causes include Hirschprung's disease, necrotizing enterocolitis, meconium plug syndrome or cystic fibrosis (2,4,5,6). Complications such as perforation are due to the thin walled appendix, and the infection spreads to the whole abdomen due to the small omentum and small capacity of the abdominal cavity therefore early diagnosis and management is important to reduce morbidity and mortality (4). Complications are also partly because of the atypical clinical presentations of acute appendicitis (and perforation) compared to what would be elicited in older children and adults (4,5,6). As reported by Gupta, different symptoms include vomiting and abdominal distension (as was present in our case). Pneumoperitoneum due to perforated appendix

was present in our case (Figure 1), however reported to be a rare finding by Roshan Ali et al. The reason for features of intestinal obstruction in our patient was due to the peritoneal contamination causing intestinal ileus (7).

The management of a perforated appendix remains to be surgery as it was done in our case (6). Surgery includes appendectomy with abdominal wash out and the appendix taken for histological analysis to rule out other causes of perforation (2,6). Generally, management outline of appendicitis is by clinical evaluation of signs and symptoms with laboratory and radiological adjuncts and by Alvarado and Pediatric Appendicitis Score (PAS) scoring system low risk patients can be discharged with watchful waiting (2). C-reactive protein (CRP) and computed tomography (CT) are considered gold standard to confirm clinical suspicion of appendicitis with relatively high sensitivity and specificity (1,8). Currently laparoscopic surgery has been increasingly popular among paediatric surgeons along with other means like percutaneous drainage of appendicular abscesses (2).

Conclusion

Acute appendicitis is a rare entity in neonates and due to the uncommon presentation and diagnosis is difficult to make therefore causes delay in the management which may lead to high morbidity and mortality.

Consent

Written informed consent was obtained from the patient's mother for publication for this case report and accompanying images. A copy of the consent is available for review by the chief editor of this journal.

Competing interest

The authors declare they have no competing interests.

Authors' contributions

JL came up with the idea, drafted and prepared the manuscript. AH, DW and JL performed the operation and reviewed patient's medical records. AS prepared and reported the radiological films. PA prepared the histology slides and the histopathology results. RP and DM provided the technical input and all authors have read and approved the final manuscript.

Acknowledgement

The authors would like to thank the mother of the child for permission for the information to be shared for further learning purposes.

References

1. Kumar J, Shepherd G, Abubacker M, et al. Trends in incidence of acute appendicitis in children. Acad J Pediatr and Neonatol. 2017;3(5):27-9.

2. Almaramhy HH. Acute appendicitis in young children less than 5 years. Italian journal of pediatrics. 2017 Dec;43(1):15.

3. El-Gohary MA. Neonatal appendicitis with perforation: A case report. Journal of Pediatric Surgery Case Reports. 2014 Jul 1;2(7):353-4.

4. Gupta V, Sharma SB. Neonatal appendicitis with perforation: A case report and review of literature. Journal of Indian Association of Pediatric Surgeons. 2005 Jul 1;10(3):179.

5. Tumen A, Chotai PN, Williams JM, et al. Neonatal perforated appendicitis attributed to localized necrotizing enterocolitis of the appendix: A review. Journal of neonatal surgery. 2017 Jul;6(3).

6. Sabrina JD, Tan CW, Nallusamy M. Neonatal perforated appendicitis. Journal of Pediatric Surgery Case Reports. 2018 Nov 1;38:66-8.

7. Ali R. Perforated Appendicitis with Massive Intraperitoneal Free Air in A Two Month Old Baby. Journal of Surgery Pakistan (International). 2015 Jan;20:1.

8. Marzuillo P, Germani C, Krauss BS, et al. Appendicitis in children less than five years old: A challenge for the general practitioner. World journal of clinical pediatrics. 2015 May 8;4(2):19.

Figure 1: Plain abdominal x-ray showing free air (arrow) under right hemi diaphragm

Figure 2: Photographs showing perforation at tip of appendix (arrow)

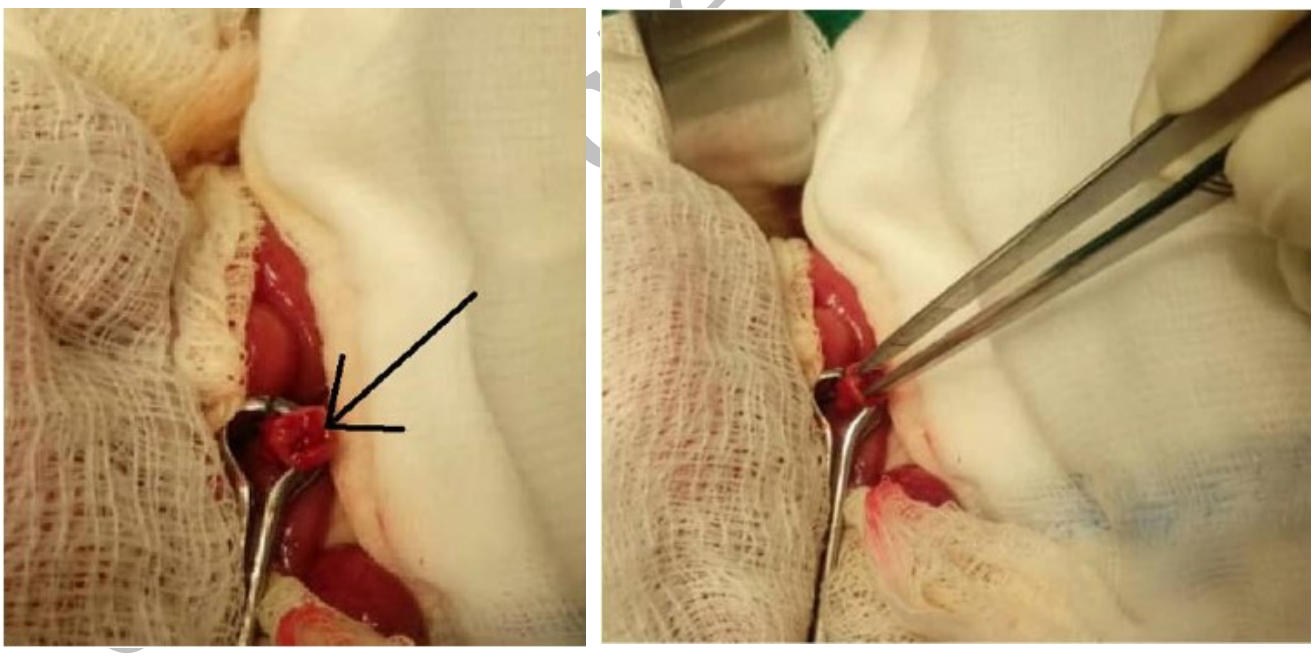

Figure 3: Histology showing inflammation of appendix

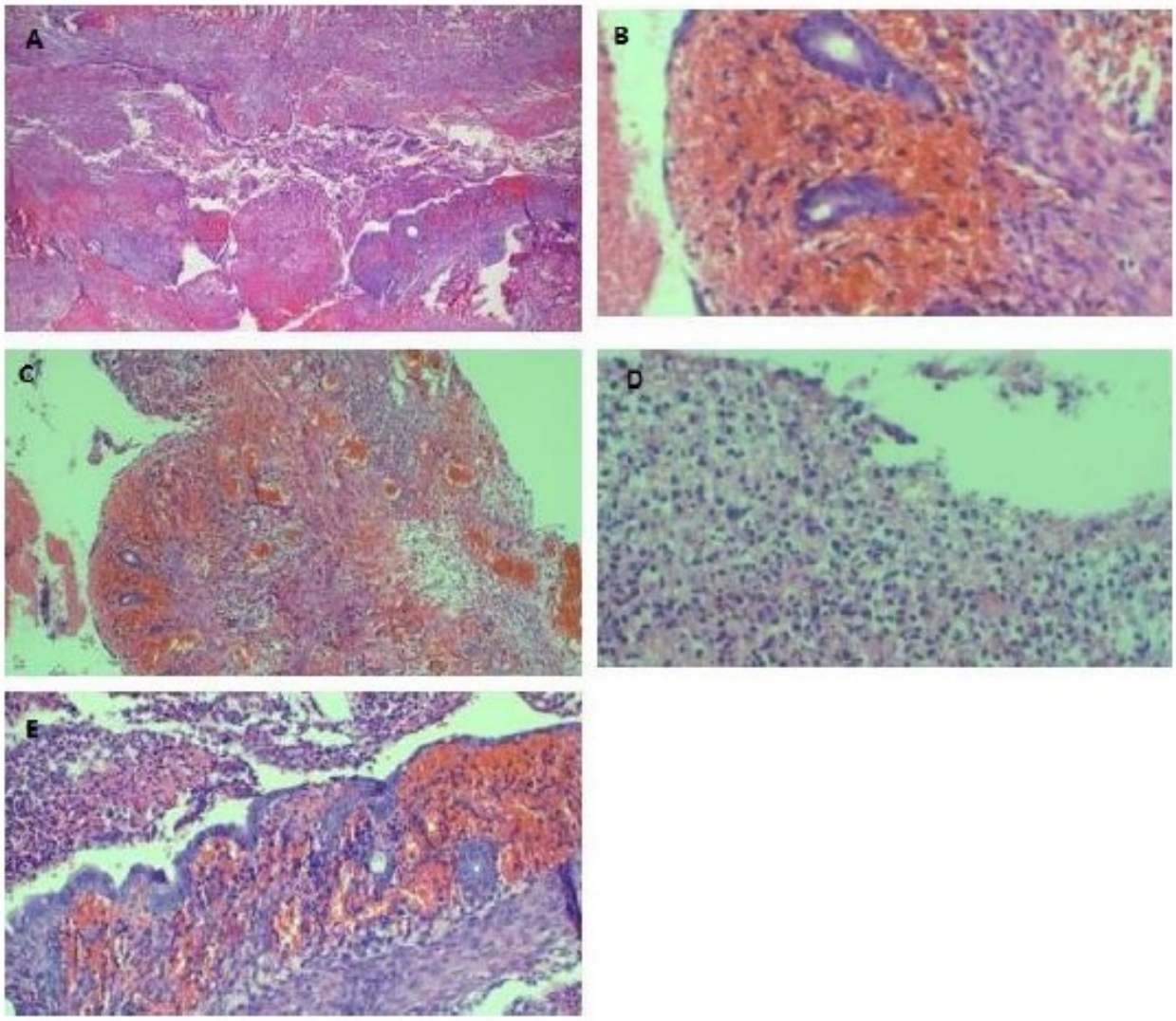

Legend: A: Low magnification micrograph showing appendicular fibrinous necrotic mucosa. B: Section showing hemorrhage in a lamina propia and loss of the lining epithelium. C: This section shows congested submucosal blood vessels, edema and atrophic glands. D: Higher magnification of the mucosa with neutrophil infiltrates within the lumen and the appendicular wall. E: The section demonstrates accumulation of inflammatory exudates (upper left) in the lumen consisting of neutrophil aggregates.