

Use of Botulinum Toxin Type A in Giant Ventral Postoperative Hernia

Protasov Andrey Vitalievich¹, Podolskiy Mikhail Yurievich¹, Mekhaeel Shehata Fakhry¹, Kulakova Anna Leonidovna¹, Kulchenko Irina Gennadievna¹, Sherreen Elhariri²

¹Department of Operative Surgery and Clinical Anatomy by I.D. Kirpatovsky, RUDN University, Moscow, Russian Federation

²Department of Surgery, International Medical University, Seremban, Malaysia

Correspondence to: Dr. Sherreen Elhariri; Email: sherreenelhariri@imu.edu.my

Received: 23-Mar-2021; Revised: 29 March 2021; Accepted: 31 March 2021; Available online: 19th May 2021

Summary

Postoperative ventral hernia represents one of the causes of anterior abdominal wall hernias. Repair of this hernia can be very challenging for surgeons, as they are associated with cardiovascular and respiratory complications, development of compartment syndrome, and high recurrence rates. Our case is a 48-year-old woman was operated on twice. The first time was in 2015 due to perforation of colonic diverticulitis for which abdominal exploration and Hartmann's procedure was performed. In 2016, the reverse of Hartmann's procedure was done. Forty days after the second operation, she noticed a small hernia in the scar area that increased rapidly. After 1 year, it became irreducible with dimensions (30X17 cm) reached the para-umbilical region without any sign of intestinal obstruction. We

decided to do hernioplasty using self-gripping mesh. Six weeks before surgery, botulinum toxin type A was injected intramuscularly to induce muscle weakness and restore the normal biomechanics of the anterior abdominal wall, facilitating closure and repair. Postoperative results and follow-up after 6 months were satisfactory.

Keywords: Botulinum toxin type A, Giant ventral postoperative hernia

DOI: <http://dx.doi.org/10.4314/aas.v18i4.10>

Conflicts of Interest: None

Funding: None

© 2021 Author. This work is licensed under the Creative Commons Attribution 4.0 International License.

Introduction

Postoperative ventral hernias (POVHs) remain one of the most difficult problems of modern herniology. They occur in 22% of cases of anterior abdominal wall hernias. The percentage of cardiovascular and respiratory system complications and the development of abdominal compartment syndrome is extremely high and reaches 20–25% (1). According to different authors, the recurrence rate in POVH hernioplasty in the long-term period is more than 40% (2).

The problem in the surgical treatment of POVH is choosing the method that can avoid the reduction of the volume of the abdominal cavity and the development of

compartment syndrome. One of the first ways to solve this problem was applied by Ramirez et al. (3) in 1990 by crossing the aponeurotic part of the external oblique muscle. This technique is called anterior separation plastic surgery. Unfortunately, this operation was associated with high traumatic damage to the tissues and consequent complications in the postoperative period (4,5).

Many methods for adequate access for POVH were developed (6–8). Besides, many laparoscopic interventions, such as totally extraperitoneal hernia repair and mini- or less-open sublay, and their

modifications were implemented (9–11). The main problem of these surgical techniques is the disturbance of the biomechanics of the anterior abdominal wall, which is associated with the impairment of anatomical structures of the oblique and transverse muscles (12,13). Contractions of this group of muscles change the location of linea alba and can cause a rupture. When a hernia occurs, the muscles lose their fixation points, and any interaction leads to an increase in the defect. The gradual reduction in the length of muscle fibers and the gradual transition to contracture will reduce the length of the anterior abdominal wall muscles. If surgeons try to close the defect of the anterior abdominal wall, the volume of the abdominal cavity (calculated as $V=L^3/6\pi^2$, where V refers to the volume of the abdominal cavity and L refers to the length of the abdominal wall in a cubic proportion and π (Pi) is the mathematic constant equal 3.14) would decrease sharply, causing the development of abdominal compartment syndrome. The development of abdominal compartment syndrome can be prevented by an increase of the circumference of the anterior abdominal wall, which compensates for the reduction in muscle length (sublay technique, transabdominal preperitoneal hernia repair). We can also reduce the number of muscles fixed to the linea alba (anterior separation, posterior separation) to decrease the mechanical strength of the anterior abdominal wall. Studying the literature, we concluded that to solve the problem, it is necessary to prevent contracture of the oblique and transverse muscles by injecting botulinum toxin type A (BTA) into the muscles (2,14–16).

The intramuscular injection of BTA acts by directly inhibiting the fibers responsible for the contraction of muscles. The inhibition of alpha-motor neurons (at the level of the neuromuscular synapse) and the inhibition of the activity of muscle spindles by inhibition of gamma-motor neuron synapse to cholinergic internal fibers lead to a decrease in gamma activity, leading to relaxation of the internal fibers of muscle spindles and reducing the activity of group Ia afferents, which decreases the activity of muscle stretching receptors as well as the efferent activity of alpha- and gamma-motor neurons.

Clinically, it causes muscle relaxation at the injection side and significant reduction of pain, and along with the process of denervation, these muscles undergo a process of reinnervation by the appearance of lateral processes of nerve terminals that leads to the restoration of muscle contractions within 4–6 months after the injection (17). The literature in animal studies showed that preoperative paralysis of the lateral muscles of the anterior abdominal wall as a result of intramuscular injections of BTA reduces intraabdominal pressure, thus allowing the closure of the hernia defect with less muscle tension (18).

Case report

A 48-year-old woman underwent two operations. The first time was in 2015 due to perforation of colonic diverticulitis for which abdominal exploration and Hartmann's procedure were performed. A year later, in 2016, the reverse of Hartmann's procedure was done. Forty days after the second operation, she noticed a small hernia in the operative scar. At 1-year follow-up, abdominal computerized tomography (CT) revealed an irreducible hernial sac (30×17 cm) and two adjacent defects (50×58 and 28×50 mm) in the middle line of the umbilical region and lower abdomen from exiting loops of the intestine and mesentery (Fig. 1). There was also an empty sac (42×27 mm) in the abdominal wall. The distance between the medial edges of the rectus muscles was 23 cm; hence, the hernia was classified as M3W4 was according to the Chevrel–Rath classification (19).

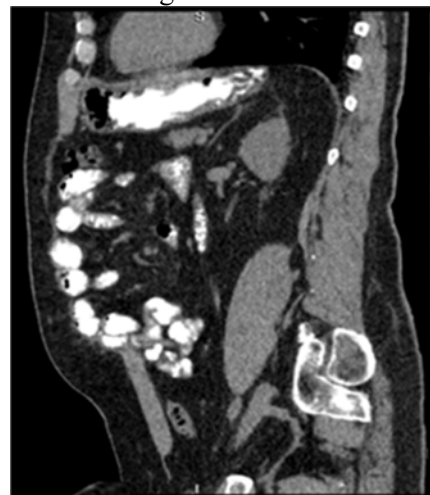

Figure 1. Computerized tomography image of the hernial defect in the sagittal projection

During ultrasound-guided studies, the anterior abdominal wall muscles were marked with colors: blue for the lateral and medial edges of the rectus muscle, green for the upper edge of the external oblique muscle, and pink for the upper edge of the internal oblique muscle (Fig. 2). The intended points of BTA injection were marked with red color, and 300 U of BTA was injected in 11 points (5 points for the internal oblique muscle and 6 for the external oblique muscle) on each side. The medial edge of the rectus abdominis muscle shifted to the center, and the oblique muscles started to relax, as indicated by an increase in their area.

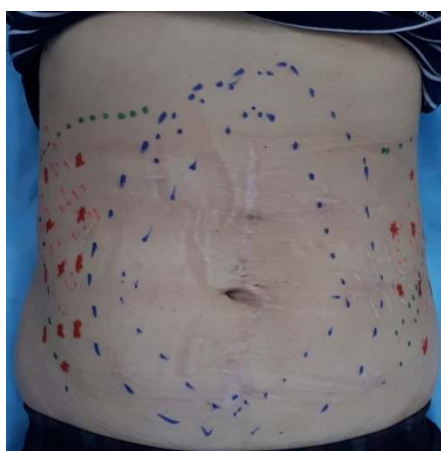


Figure 2. Marking of the anterior abdominal wall

Under general anesthesia, hernioplasty was performed 6 weeks after BTA injection. We excised the old scar and subcutaneous tissue, opened the hernial sac, and reduced the contents (loops of the small intestine). The hernial sac was multi-exposed, excised, and removed as one flap with the umbilical ring. Furthermore, we found four other defects in the aponeurosis with sizes ranging from 2×2 cm up to 4×3 cm. All the defects were connected, the defective tissue of the fascia was excised with some multiple granulomas containing the old suture materials; then we mobilized the edges of the aponeurosis.

We incised the posterior rectus sheath longitudinally and mobilized the rectus abdominis muscles anteriorly. Then we incised the posterior sheath 1 cm medial to the arcuate line to avoid injury of the neurovascular bundles. We made edge-to-edge polytrimethylene carbonate (Maxon®; Medtronic, Medtronic Parkway, MN, USA) stitches to the linea alba above the navel and the

transverse fascia. The peritoneum under the navel was placed, and we formed a bed for the mesh with size of 25×21 cm.

We used mesh Bard Adhesix® (BD, Franklin Lakes, NJ, USA) self-adhering hernia mesh (30×30 cm). It was cut according to the size and shape of the prepared bed (Fig. 3). After mesh placement, the anterior rectus sheath was sutured over the mesh by continuous Maxon sutures with medialization of the rectus abdominis muscles (Fig. 4). When suturing the anterior abdominal wall, a drain was installed in the subcutaneous tissue, which was sutured with separate catgut sutures.

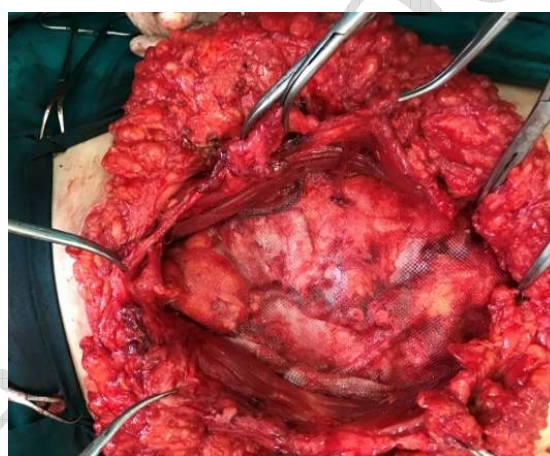

Figure 3. Layout of the mesh.

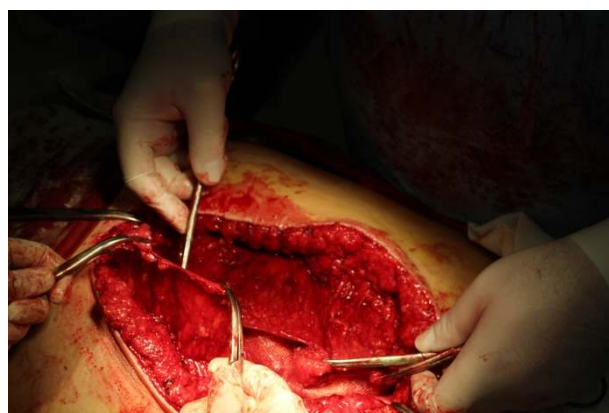


Figure 4. Suturing the anterior wall of the rectus sheath

The postoperative period went without any complications or signs or symptoms of respiratory failure. Suction drainage was removed on day 3. The patient was discharged on day 6, and skin sutures were removed on day 10. The patient underwent follow-up abdominal CT (for the anterior abdominal wall) at 1, 3,

and 6 months (Fig. 5). On the 4th month, the recovery was full, and the motor function of the oblique muscles was regained.

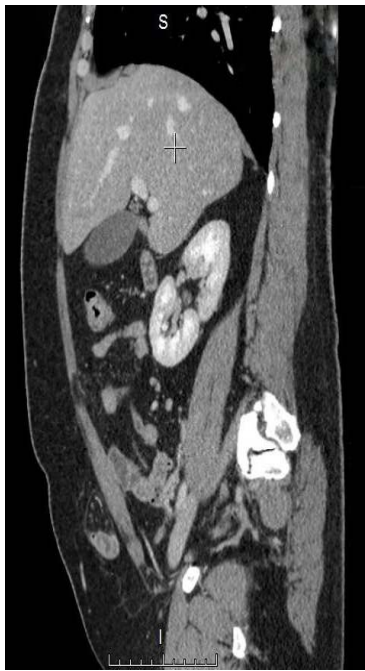

Figure 5. Computerized tomography image after 6 months: sagittal projection

Discussion

We presented a case wherein BTA injection was used for hernioplasty in a giant ventral postoperative hernia in order to avoid abdominal compartment syndrome. Different component separation techniques were the gold standard in the management of giant ventral hernias. The synergetic effect of BTA injections with these techniques leads to abdominal wall compliance through the elongation and thinning of the musculature and decrease in the mean transverse defect size. The tissues will heal with minimal tension, thus reducing the risk of hernia recurrence and decreasing pain after surgery, which minimizes the need for narcotic analgesia (20).

The recurrence rate after CST for the repair of giant incisional hernias was 4–32%. In the research done by Soltanizadeh et al. (15) in six cohort studies, which included 133 patients, recurrence occurred in 2 patients (9%) in the BTA group compared with 6 patients (14%) in the control group after 18 months.

The timing and dose of BTA injection are essential factors for reaching the optimal effect. In our case, we choose to inject BTA 6 weeks preoperatively according to the review of the literature by Soltanizadeh et al. (15), and the paralyzing effect reached a maximum 2 weeks after injection and declined gradually after 10 weeks. More recently, the results of 10 studies reviewed by Elhage et al. (20) were functional denervation within 2 days, with peak effect after 4–6 weeks leading to flaccid paralysis.

In our case, we chose to inject a dose of 300 U BTA. As in a comparable study by Soltanizadeh et al. (15), who performed radiological assessment after 4 weeks, administration of 100 U resulted in a small and non-significant transverse reduction of the hernia defect. With the injection of 300 U BTRA, the reduction was up to 58%, which showed a similar effect to studies (2,16) that used 500 U. Thus, Soltanizadeh et al. (15) recommended an optimal total dose of 300 U BTA.

Preoperative ultrasound is important for the identification of the muscle of the anterior abdominal wall and hernia defect dimensions and its contents. In our case, we used a suitable-size mesh (30×30 cm) that is bigger than the hernial defect and a self-adherent mesh to decrease the time used for mesh fixation.

Anterior abdominal muscles undergo a process of reinnervation, which leads to the restoration of muscle contractions within 4–6 months after the injection (18). Abdominal CT performed at 4-month follow-up showed that the motor function of the oblique muscles was restored and that the patient's recovery was full.

The synergetic effect of BTA and adjuvant CST was appropriate in the treatment of patients with large ventral hernias. Preoperative BTA injection in the muscles of the anterior abdominal wall to treat patients with large ventral hernias assists in the anatomical reconstruction of the anterior abdominal wall. The function of the oblique and transverse muscles return to normal, the rectus muscles medialize, and the normal biomechanics of the anterior abdominal wall is restored, thus enabling fascial closure of large defects. Thus, we highly recommend preoperative BTA injection, which gives promising and safe results.

Conclusion

Preoperative BTA injection to the muscles of the abdomen in the treatment of patients with large ventral hernias provides the anatomical reconstruction of the anterior abdominal wall, returns the oblique and transverse muscles to their normal functioning, medializes the rectus muscles, restores the normal biomechanics of the anterior abdominal wall and enabling closure of large defects.

References

1. Gain YM, Bogdan VG, Popkov OV. Abdominal compartment syndrome. *Nov Khirurg.* 2009;17:168–82.
2. Elstner KE, Read JW, Rodriguez-Acevedo O, et al. Preoperative chemical component relaxation using Botulinum toxin A: enabling laparoscopic repair of complex ventral hernia. *Surg Endosc.* 2017;31:761–68.
3. Ramirez OM, Ruas E, Dellon AL. “Components separation” method for closure of abdominal-wall defects: an anatomic and clinical study. *Plast Reconstr Surg.* 1990;86:519–26.
4. De Silva GS, Krpata DM, Hicks CW, et al. Comparative radiographic analysis of changes in the abdominal wall musculature morphology after open posterior component separation or bridging laparoscopic ventral hernia repair. *J Am Coll Surg.* 2014;218:353–7.
5. Krpata DM, Blatnik JA, Novitsky YW, et al. Posterior and open anterior components separations: a comparative analysis. *Am J Surg.* 2012;203:318–22.
6. Carbonell AM, Cobb WS, Chen SM. Posterior components separation during retromuscular hernia repair. *Hernia.* 2008;12:359–62.
7. Novitsky YW, Elliott HL, Orenstein SB, et al. Transversus abdominis muscle release: a novel approach to posterior component separation during complex abdominal wall reconstruction. *Am J Surg.* 2012;204:709–16.
8. Protasov AV, Smirnova ED. Non-fixation method of abdominal wall hernia repair. *RUDN J Med.* 2011;(3):42–5.
9. Bittner R, Bingener-Casey J, Dietz U, et al. Guidelines for laparoscopic treatment of ventral and incisional abdominal wall hernias (International Endohernia Society [IEHS])—part III. *Surg Endosc.* 2014;28:380–404.
10. Ivanov YV, Panchenkov DN, Terehin AA, et al. Allohernioplasty laparoscopic postoperative ventral hernias. *J Exp Clin Surg.* 2017;10:10–20.
11. Vorst AL, Kaoutzanis C, Carbonell AM, et al. Evolution and advances in laparoscopic ventral and incisional hernia repair. *World J Gastrointest Surg.* 2015;7:293–305.
12. Botezatu AA. Abdominal wall reconstruction at the hernioplasty of the big and huge, recurrent median hernias. *RUDN J Med.* 2013;(1):58–63.
13. Hicks CW, Krpata DM, Blatnik JA, et al. Long-term effect on donor sites after components separation: a radiographic analysis. *Plast Reconstr Surg.* 2012;130:354–9.
14. Ibarra-Hurtado TR, Nuño-Guzmán CM, Miranda-Díaz AG, et al. Effect of botulinum toxin type A in lateral abdominal wall muscles thickness and length of patients with midline incisional hernia secondary to open abdomen management. *Hernia.* 2014;18:647–52.
15. Soltanizadeh S, Helgstrand F, Jorgensen LN. Botulinum toxin A as an adjunct to abdominal wall reconstruction for incisional hernia. *Plast Reconstr Surg Glob Open.* 2017;5:e1358.
16. Zendejas B, Khasawneh MA, Srwantstyan B, et al. Outcomes of chemical component paralysis using botulinum toxin for incisional hernia repairs. *World J Surg.* 2013;37:2830–7.
17. Dressler D. Clinical applications of botulinum toxin. *Curr Opin Microbiol.* 2012;15:325–36.
18. Cakmak M, Caglayan F, Somuncu S, et al. Effect of paralysis of the abdominal wall muscles by botulinum A toxin to intraabdominal pressure: an experimental study. *J Pediatr Surg.* 2006;41:821–5.
19. Chevrel JP, Rath AM. Classification of incisional hernias of the abdominal wall. *Hernia.* 2000;4:7–11.
20. Elhage SA, Deerenberg EB, Shao JM, et al. The use of botulinum toxin A in chemical component separation: a review of techniques and outcomes. *Plast Aesthet Res.* 2020;7:16.